Copyright © 2019 by The Journal of Bone and Joint Surgery, Incorporated

Current Concepts Review

Knee Arthrodesis After Failed Total Knee Arthroplasty

Asim M. Makhdom, MD, MSc, FRCSC, Austin Fragomen, MD, and S. Robert Rozbruch, MD

Investigation performed at the Hospital for Special Surgery, Weill Cornell Medicine, Cornell University, New York, NY

Downloaded from http://journals.lww.com/jbjsjournal by 1mhtSo9F6TkBmpGAR5GLp6FT3v73JgoS8Zn360/N4fAEQXu6c15Knc+cXP2J5+wbQY2nVcoOF2Dk3Zd0BSqmOXRD8WUDFCPOJ9CnEHMNOmtlbs3S0ykA== on 04/12/2019

- Knee arthrodesis after failure of a total knee arthroplasty (TKA) because of periprosthetic joint infection (PJI) may provide superior functional outcome and ambulatory status compared with above-the-knee amputation.
- The use of an intramedullary nail (IMN) for knee arthrodesis following removal of TKA components because of a PJI may result in higher fusion rates compared with external fixation devices.
- The emerging role of the antibiotic cement-coated interlocking IMN may expand the indications to achieve knee fusion in a single-stage intervention.
- Massive bone defects after failure of an infected TKA can be managed with various surgical strategies in a single-stage intervention to preserve leg length and function.

Primary total knee arthroplasty (TKA) is a common procedure with a reported increase of 162% from 1991 to 2010 in the United States[1,2]. From 2005 to 2030, it is projected that the number of TKA procedures will grow by 673% or 3.5 million. Furthermore, the demand for TKA revision because of failure after primary TKA is projected to grow by 601% in 2030[1]. These numbers are concerning since multiple failed revisions may result in an unreconstructible total knee replacement. Knee arthrodesis in such circumstances can salvage the knee to provide a stable extremity and restore the weight-bearing ability. It is estimated that 0.21% to 1.11% of failures after TKA result in knee arthrodesis[3,4]. In a recent report, the cumulative incidence of knee arthrodesis after failure of TKA because of periprosthetic joint infection (PJI) over 15 years was 0.26%[5].

In some clinical circumstances, knee arthrodesis may provide superior functional results and better ambulatory status than transfemoral or above-the-knee amputations, particularly for patients who have had recurrent PJI of the knee and underwent 2-stage revision[6,7]. In addition, transfemoral amputations after failure of an infected TKA may pose a higher risk of mortality compared with knee arthrodesis[8,9]. Other treatment alternatives such as resection arthroplasty or long-term suppressive antibiotics for recurrent PJIs are generally reserved for patients with more severe preoperative disability and medical comorbidity and those who are not candidates to undergo further surgical intervention[10-12].

In this article, we review the current indications, principles, techniques, and outcome data, and propose a treatment algorithm for knee arthrodesis after failure of a TKA because of infection.

Indications for and Timing of Knee Arthrodesis After a Failed TKA

Currently, knee arthrodesis is a treatment option following a failed unreconstructible total knee replacement. The most common indication for fusion after failure of a TKA is recurrent PJI[5,13,14]. Other indications include an unreconstructible extensor mechanism, large bone defects, a stiff painful knee after TKA, and poor soft-tissue coverage.

The choice and timing for management of an infected 1-stage or 2-stage revision TKA have been debated. Available options include repeat revision TKA, knee arthrodesis, transfemoral amputation, and resection arthroplasty. These can be combined with long-term suppressive antibiotic therapy.

Disclosure: The authors indicated that no external funding was received for any aspect of this work. On the **Disclosure of Potential Conflicts of Interest** forms, *which are provided with the online version of the article*, one or more of the authors checked "yes" to indicate that the author had a relevant financial relationship in the biomedical arena outside the submitted work (http://links.lww.com/JBJS/F151).

Choosing among these treatment options often raises a clinical and ethical dilemma regarding informed consent, respecting the patient's autonomy, and the surgeon's recommendations. This dilemma has been well described by Capozzi et al.[15]. When knee arthrodesis is compared with repeat revision TKA after a failed revision procedure for an infected TKA, the question that must be then answered would be which of these 2 procedures will better control the infection? Determining the answer is often difficult secondary to the lack of data that directly compare these procedures with matched patient demographics, bone quality, virulence of infecting organisms, comorbidities, and preoperative ambulatory and functional status. One problem regarding knee arthrodesis after failed TKA is that it is commonly perceived as an unfavorable option by most surgeons and patients, and therefore is often delayed or discarded. The issue surrounding the timing of knee arthrodesis in such patients is that by the time the patient and the surgeon capitulate to the idea of arthrodesis, it may no longer be feasible secondary to substantial bone loss as a result of multiple revisions. Functional outcomes and union rates after knee arthrodesis can be jeopardized in patients who have had multiple revisions secondary to poor bone stock and major bone loss[16-19].

It has been suggested that fusing the knee could produce functional results comparable with revision TKA in cases of recurrent PJI[4,20]. Recent reports have also shown that 2-stage revisions in patients with PJIs are associated with substantial morbidity and mortality, and the reported success rates should be interpreted with caution. Gomez et al. studied 504 patients with chronic PJI and found that approximately 20% of the patients never underwent the second-stage reimplantation[21]. The authors suggested that previous reports on the outcome of 2-stage revision did not account for the mortality of these patients as well as patients who never underwent reimplantation. Similarly, Cancienne et al. recently showed that 38% of 18,533 patients did not undergo a second-stage revision after failure of an infected TKA[22]. These results have led some authors to question the success of a 2-stage revision strategy[23,24]. Thus, it is important to recognize that patient selection bias for 2-stage revision may contribute to the variability of reported success rates among different authors.

Few studies have investigated the outcome of subsequent procedures after failed 2-stage revisions. Kheir et al., in a recent study, showed that repeat surgical intervention after a failed 2-stage revision for PJI was associated with poor outcomes[25]. Those authors found that infection control, in this population, after a repeat 2-stage revision failed in 38.4% of patients. Wu et al. determined the utility values of health states after various treatment options that could be performed following 2-stage revision for an infected TKA[26]. Those authors included transfemoral amputation, suppressive antibiotics, knee arthrodesis, and repeat 2-stage revision. On the basis of their sensitivity analysis, they found that knee arthrodesis was most likely to yield the highest expected quality of life after failing 1 attempt at a 2-stage revision. Taken together, these studies highlight the importance of early counseling and management of patients' expectations after failure of an infected TKA and demonstrate that knee arthrodesis may be considered after 1 failed 2-stage revision.

Contraindications

The contraindications to knee arthrodesis include a prior contralateral knee arthrodesis or transfemoral amputation or an ipsilateral hip arthrodesis[13]. These associated conditions would affect the compensatory mechanisms for walking after knee arthrodesis and considerably increase the energy expenditure. Since knee arthrodesis increases the stress transfers across the ipsilateral hip and ankle, it is important to evaluate the ipsilateral hip and ankle arthritis and possibly address those joints while preserving their mobility. Additionally, degenerative lumbar spine disease is considered a relative contraindication as pelvic tilt and compensatory forces, after the knee arthrodesis, can considerably worsen the degenerative spinal pathology[27].

Principles of Knee Arthrodesis

The key principles for knee arthrodesis after infection at the site of a TKA include preoperative host optimization, infection control, optimal knee fusion position, maximum bone contact at the fusion site, and achieving desirable leg length.

Preoperatively, improving medical conditions is extremely important. Modifiable risk factors such as diabetic control, smoking, and nutritional status or medications that affect wound-healing should be addressed. Infection control should be managed both locally and systemically. Consulting an infectious disease specialist is often necessary to guide antimicrobial treatment. The surgical methods of local control include 1-stage or 2-stage arthrodesis (described in the section below). Any previous surgical scars and soft-tissue coverage flaps may necessitate plastic surgery consultation.

The position of the fused tibia and femur in the coronal and sagittal planes is controversial. Some authors have advocated full knee extension to preserve limb length, whereas others have advocated 10° to 15° of flexion to slightly shorten overall length and improve gait speed and sitting position[28,29]. It is recommended that the ipsilateral lower extremity be shorter than the contralateral one with a leg length discrepancy (LLD) of approximately 1.5 cm to allow easier clearance during the swing phase of gait[30]. While this goal is commonly cited in the literature, it is often not possible to achieve target shortening (e.g., 1.5 cm) secondary to bone loss after explantation of TKA components. The average LLD (and standard deviation) after TKA explantation was reported as 6.6 ± 2.8 cm in 1 study[31]. The surgeon can measure and estimate the preoperative bone loss and predicted LLD after debridement and/or TKA explantation (Fig. 1). The decision is then made whether to accept the LLD. Generally, LLD of <5 cm can be accepted in elderly patients and treated with a shoe lift[29,30]. Conversely, younger patients and/or a substantial LLD postoperatively may benefit from a lengthening procedure. In patients with major comorbidities that preclude a lengthening procedure, alternative methods (described in the following sections) should be considered to optimize the leg length. Five to 7° of anatomical femoral valgus has been suggested to be the optimal alignment in the coronal

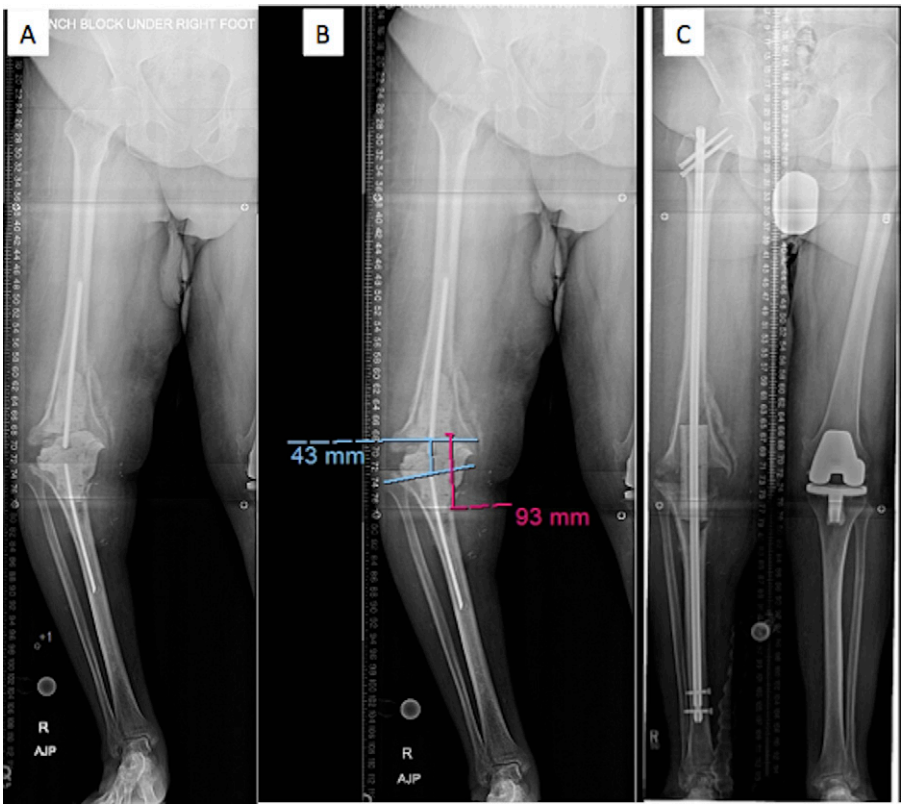

Fig. 1

Figs. 1-A, 1-B, and 1-C An elderly patient who had recurrent periprosthetic infections after failed TKA. He underwent explantation of the prosthesis at another institution. **Fig. 1-A** Preoperative anteroposterior radiograph. **Fig. 1-B** The preoperative bone loss was measured as 4.3 cm (vertical blue line). Additional bone resection was required on both the femur and tibia to attain maximum contact. The predicted LLD after debridement was estimated to be 9.3 cm (red line). **Fig. 1-C** Postoperative radiograph showing the long antibiotic-impregnated cement-coated interlocking IMN and cannulated antibiotic-loaded cement spacer technique to bridge the bone defect and preserve length.

plane to help decrease the varus stress on the ipsilateral hip and ankle and to potentially minimize future pain in these joints[32]. A trial period of placing the affected limb in a cylindrical cast or knee immobilizer to mimic the postoperative knee fusion position may provide insight into the potential problems that the patient may face postoperatively during ambulation[13].

Maximum bone contact at the arthrodesis site is key to achieving union and may not be feasible to achieve acutely after explantation of a TKA prosthesis. Additionally, in some cases, acute shortening to attain bone contact may also compromise primary soft-tissue closure[31].

One-Stage Versus 2-Stage Arthrodesis

Arthrodesis after a failure of an infected TKA can be done in 1 or 2 stages. In 2-stage arthrodesis, debridement and irrigation, removal of components, and insertion of an antibiotic cement spacer are performed. Knee arthrodesis is then performed after 6 to 8 weeks, if the infection has cleared. One-stage arthrodesis includes debridement and irrigation, removal of components, and a knee arthrodesis as a single surgical procedure.

Many authors have shown that the presence of internal fixation implants that are used in 1-stage arthrodesis is a risk for development of a deep infection and have advocated 2-stage arthrodesis[14,33,34]. In contrast, several studies have shown that 1-stage arthrodesis by using an intramedullary nail (IMN) or external fixation devices can be a safe and effective option in the absence of virulent organisms or polymicrobial infections[5,31,35,36]. Regardless of the staging method, it is imperative to recognize that the host susceptibility[37] contributes to the success of infection control and/or eradication.

In the past decade, the use of antibiotic cement-coated interlocking IMNs has shown promising results and may expand the indications for 1-stage arthrodesis after infection at the site of a TKA. In some cases, using this technique may obviate the need for alternative methods such as using external fixation. Several reports have demonstrated the utility of antibiotic cement-coated IMNs to control the infection and obtain fusion and/or union after failed procedures for infected TKAs, infected ankle joints, and tibial osteomyelitis[31,38-40].

IMNs

The advantage of using IMNs includes higher union rates than those found in direct comparison with the use of external fixation devices (Table I)[5,33-36,41-52]. However, all of the reported studies were retrospective in nature and subject to selection bias. It is unclear whether patients with most virulent infections,

TABLE I Previous Studies on Knee Arthrodesis After Failure of Infected TKAs*

Study	Level of Evidence	No. of Patients with Infected Failed TKA	Staging/Method of Arthrodesis†	Fusion Rate *(%)*	Complications	Mean Follow-up Period†
Comparison of the use of an IMN and external fixation						
Mabry et al.[33] (2007)	III	85	Staging (NR)/external fixation (n = 61) and short modular and nonmodular IMN (n = 24)	96% (IMN group) versus 67% (external fixation group)	Recurrent infection (n = 5)	13 mo
Yeoh et al.[50] (2008)	III	17	1 stage (n = 6) and 2 stage (n = 11)/short modular IMN (n = 11) and monolateral external fixator (n = 6)	91% (IMN group) versus 33% (external fixator group)	Postop. infections (n = 5) in IMN group and (n = 4) in external fixator group; nonunion (n = 4) in external fixator group	NR
Domingo et al.[51] (2004)	III	21	2 stage (n = 21)/short modular (n = 10) and monoplanar or biplanar external fixation (n = 11)	90% (IMN group) versus <50% (external fixation group)	Recurrent infection (n = 1) in IMN group; pin site infections (n = 5) in external fixation group	NR
Kuchinad et al.[31] (2014)	IV	21	2 stage (n = 16) and 1 stage (n = 5)/long antibiotic-coated IMN (n = 5) and circular fixator (n = 16)	100% (IMN) versus 93% (circular fixator)	Nonunion (n = 1), vascular emboli (n = 1), and wound infection (n = 1) in circular fixator group	42 mo
Klinger et al.[48] (2006)	IV	20	1 stage (n = 7) and 2 stage (n = 13)/ monolateral external fixator (n = 18) and short modular IMN (n = 2)	85%	Nonunion (n = 2) and recurrent infection (n = 1) in external fixation group	4.5 yr
Van Rensch et al.[49] (2014)	IV	13	2 stage/short modular nail (n = 5)/external fixation (n = 8)	80% (IMN group) versus 50% (external fixation group)	Nonunion (n = 3) and recurrent infection (n = 1) in external fixator group; recurrent infection (n = 1) in IMN group	NR
Gottfriedsen et al.[5] (2016)	IV	152	1 stage (n = 89) and 2 stage (n = 71)/IMN (n = 32) and external fixation (n = 120)	84% (IMN group) versus 61% (external fixator group)	Nonunion or persistent infection (n = 34; group was not specified)	19.2 mo
Use of IMNs						
Bargiotas et al.[34] (2007)	IV	12	2 stage (n = 12)/long IMN	83%	Nail breakage (n = 1) and recurrent infection (n = 1)	4.1 yr
De Vil et al.[41] (2008)	IV	15	2 stage (n = 15)/long IMN or modular short IMN	60%	Septic nonunion (n = 4)	5 yr
Friedrich et al.[35] (2017)	IV	37	2 stage (n = 37)/short modular IMN	86.5%	Recurrent infection (n = 5)	31 mo
Gallusser et al.[36] (2015)	IV	15	2 stage (n = 15)/short modular IMN	75%	Nonunion (n = 1), deep infection (n = 1), and peroneal nerve palsy (n = 1)	33 mo
Leroux et al.[43] (2013)	IV	17	2 stage (n = 17)/long IMN	94%	Tibial fracture (n = 1), femoral fracture (n = 1, recurrent infection (n = 1), and peroneal nerve palsy (n = 2)	16 mo

continued

TABLE I (*continued*)

Study	Level of Evidence	No. of Patients with Infected Failed TKA	Staging/Method of Arthrodesis†	Fusion Rate *(%)*	Complications	Mean Follow-up Period†
Garcia-Lopez et al.[44] (2008)	IV	18	1 stage (n = 7) and 2 stage (n = 11)/long IMN	80%	Nonunion (n = 4), peroneal nerve palsy (n = 1), and intraop. fracture (n = 1)	20 mo
Razii et al.[45] (2016)	IV	12	1 stage (n = 9) and 2 stage (n = 3)/long IMN	92%	Nonunion (n = 3)	48.5 mo
Talmo et al.[46] (2007)	IV	29	1 stage (n = 4) and 2 stage (n = 25)/long IMN	83%	Nail breakage (n = 2) and recurrent infection (n = 3)	48 mo
Incavo et al.[52] (2000)	IV	17	2 stage (n = 17)/long IMN or modular IMN (n = 17)	100%	Delayed union (n = 1)	30 mo
Use of external fixation						
Bruno et al.[47] (2017)	IV	15	1 stage (n = 15)/circular fixator	72%	Refracture after frame removal (n = 2) and recurrent infection (n = 2)	36 mo

*Studies reporting on a minimum of 10 patients over the previous 2 decades (1997 to 2017). †NR = not reported.

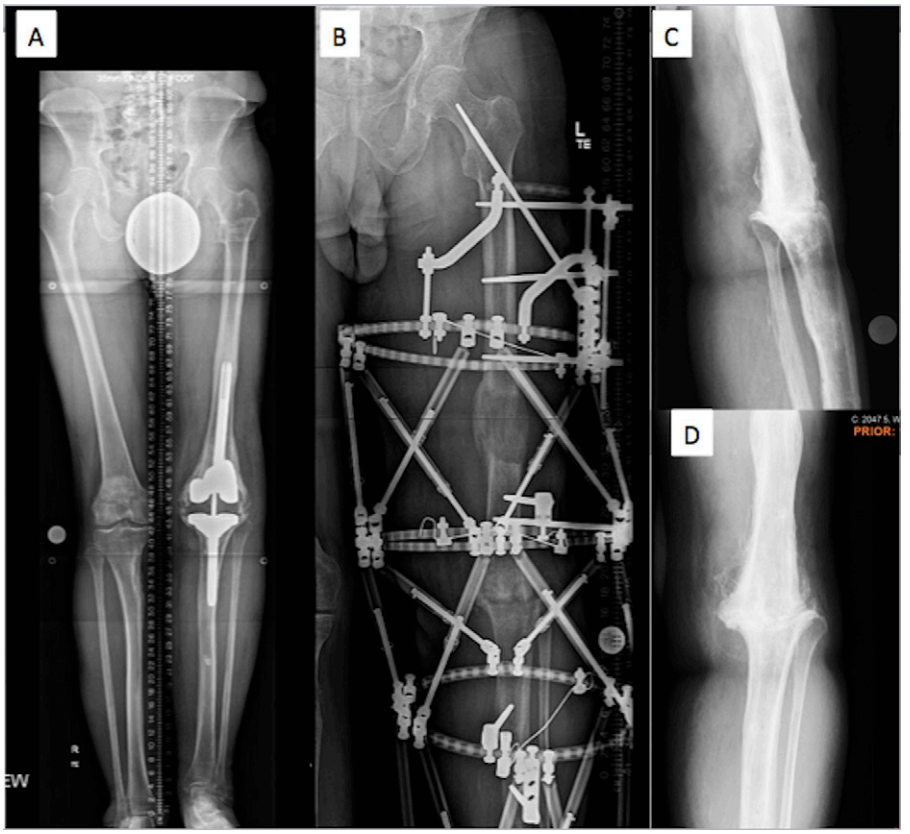

Fig. 2

Figs. 2-A through 2-D A patient who had recurrent periprosthetic infections after failed TKA with a predicted LLD of 7 cm. **Fig. 2-A** Preoperative anteroposterior radiograph of the lower extremities. **Fig. 2-B** Knee arthrodesis was performed using a circular fixation device with simultaneous femoral lengthening to correct the LLD. **Figs. 2-C and 2-D** Lateral and anteroposterior radiographs of the left knee at the time of the final follow-up visit.

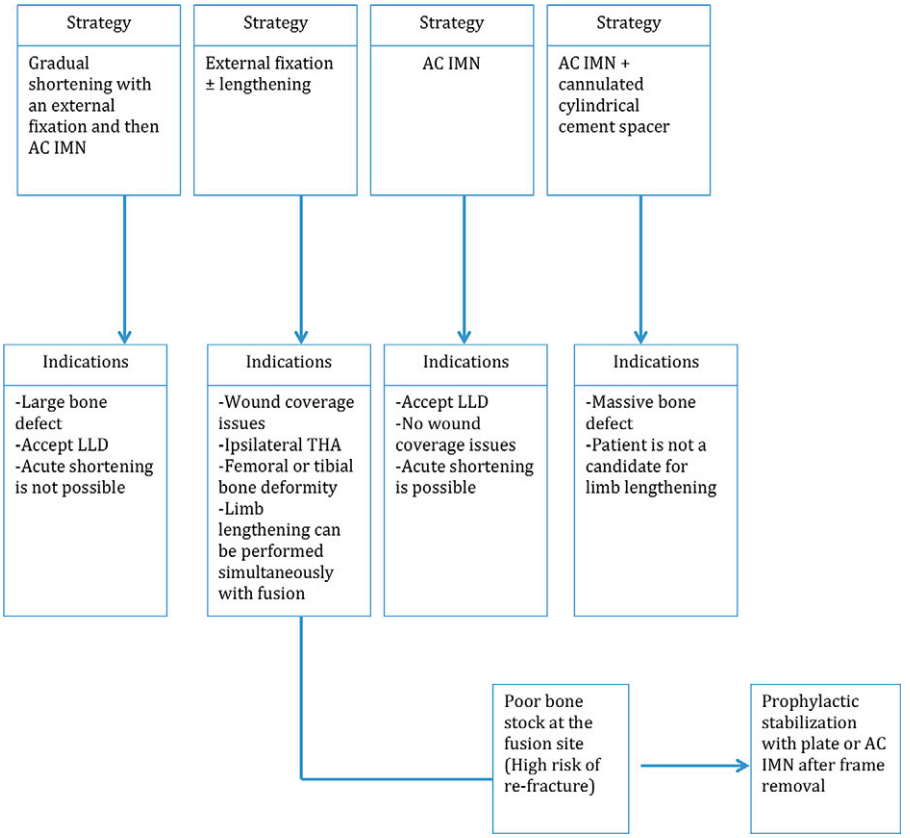

Fig. 3

Diagram of our surgical strategies for knee arthrodesis after failure of an infected TKA. AC IMN = antibiotic cement-coated intramedullary nail, LLD = leg length discrepancy, and THA = total hip arthroplasty.

poor soft tissue, and immune response underwent arthrodesis using an external fixation device rather than IMNs. Another advantage of IMNs is that most surgeons are more familiar with the surgical technique of IMN use than they are with applying a circular external fixator.

The disadvantages of IMNs include prolonged operative time and increased blood loss[51]. Using a long IMN makes the knee fusion position more difficult to control. MacDonald et al. recommended inserting the long IMN with its bow being directed anteromedially to gain some flexion and valgus at the knee[13]. The contraindications to using IMNs include poor soft-tissue coverage, active infection, ipsilateral hip replacement, a large defect that cannot be acutely shortened, and/or a substantial ipsilateral femoral or tibial deformity. Finally, when an IMN technique is used, the LLD cannot be corrected unless a future surgical intervention is planned to lengthen the extremity. The additional lengthening procedure can be performed by a "lengthening over the nail" technique or by an exchange nailing with a motorized internal femoral or tibial lengthening nail[53].

Several types of IMNs have been used to obtain knee fusion. These include short nonmodular, short modular, and long interlocking nails. Long IMNs are inserted through an antegrade approach through the piriformis fossa after reaming and following the distal femoral and proximal tibial preparation and debridement at the fusion site through the knee incision. The IMN is then interlocked both proximally and distally. Modular and nonmodular short nails are typically inserted through the knee incision after bone preparation. Modular nails have 2 separate components and are connected with a coupler device. This feature allows the surgeon to improve the nail fit into the canal when there is a mismatch in the canal diameter between the femur and the tibia. Nonmodular nails such as the Huckstep nail provide the ability to use multiple locking screws to add to the construct stability. Short modular and nonmodular nails can be used in the presence of ipsilateral hip replacement or femoral or tibial deformity. However, removing these nails is challenging and requires making cortical bone windows that may jeopardize the fusion site[52,54].

Recently, the use of antibiotic cement-coated interlocking IMNs has been proposed to achieve fusion and infection control after failure of a TKA[31]. The potential advantages of this technique include preventing or treating a preexisting infection in a single-stage surgical intervention.

External Fixator

External fixation devices have several advantages over IMNs. The application of the external fixator can be performed through small incisions for pins and/or wires, and therefore blood loss is minimized. Using a circular fixator offers the option of gradual shortening of bone until docking of bone ends is

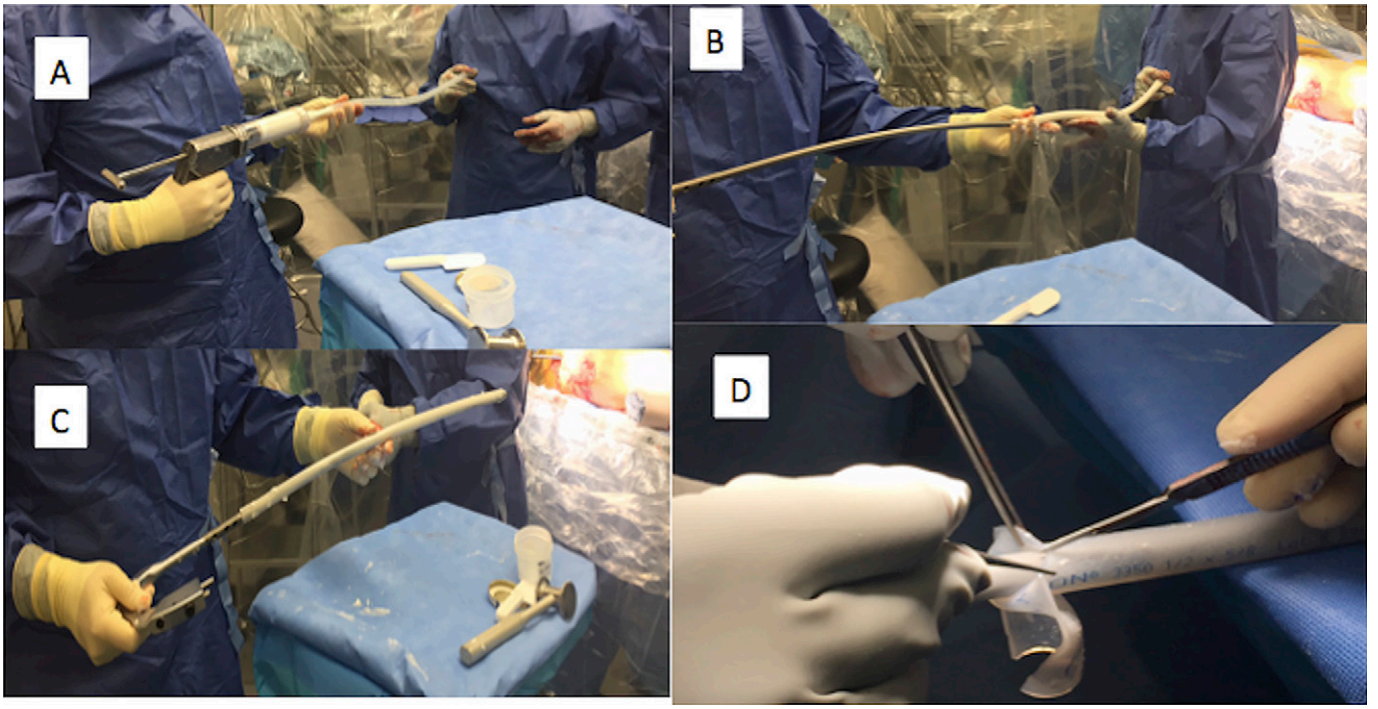

Fig. 4

Figs. 4-A through 4-D Photographs demonstrating the technique of coating IMNs with antibiotic-impregnated cement. **Fig. 4-A** The antibiotic cement mixture is inserted (using a cement gun) into a silicone tube (authors' preferred method) or chest tube. The distal interlocking holes are filled with bone wax in advance and before the nail insertion into the tube. **Fig. 4-B** The nail is then inserted into the silicone tube while an assistant plugs the distal end of the tube to avoid cement leakage and to maximize the cement volume around the nail. **Fig. 4-C** The cement is allowed to harden. **Fig. 4-D** After the cement is hardened, the mold is removed and the nail is ready to insert. We typically overream the canal by 1 mm more than the outer cement-coating diameter. This minimizes the possibility of disrupting the cement mantle when the nail is impacted into the canal.

achieved. This is beneficial when a large bone defect is encountered after explantation of TKA components. In these cases, acute shortening to obtain bone contact at the fusion site is not possible and may compromise the soft-tissue closure and/or may lead to loss of palpable distal pulses. Circular fixation is also capable of simultaneously lengthening the femur and/or tibia (Ilizarov bone transport technique) at a different level while compressing the fusion site (Fig. 2). The external fixator is a good option in patients with poor soft-tissue coverage and when internal fixation is contraindicated.

The disadvantages of external fixation include the high rate of pin-site infections[31]. Stress fractures through stress risers at the pin site and neurovascular injuries also have been reported[13]. The surgical technique of Ilizarov-type circular fixators is not familiar to many surgeons and requires experience and prior training. Another possible disadvantage is that, on the basis of retrospective case series, the union rates of knee fusion with external fixation are lower than those with IMNs (Table I). When the bone quality is poor, the fusion site can be precarious and vulnerable to refracture after frame removal. This can be addressed with prophylactic nailing or plating at the time of frame removal.

Circular fixation is most commonly utilized for knee arthrodesis because of its excellent biomechanical stability compared with uniplanar or biplanar fixators[55]. The modern hexapod frames offer versatility to easily adjust the fusion position and obtain the desired alignment with the help of specialized software. The desired angular, rotational, translational, and length parameters as well as initial strut lengths (for hexapod struts) are entered into a specialized software program that addresses deformity corrections. The software then enables a prescription of strut adjustments that need to be followed until the deformity is gradually corrected.

Compression Plating

Compression plating is not commonly utilized as the primary method of arthrodesis after failed TKA. Although plating can provide rigid fixation, wound closure over the anterior plates may predispose to postoperative infection or chronic pain. Another disadvantage is that, postoperatively, weight-bearing cannot be advanced as quickly as with IMNs or circular fixators. Few authors have reported on using a dual plating technique after failed TKA. Nichols et al. investigated this technique in 11 patients after failed TKA, and all patients obtained a solid fusion[56]. However, femoral stress fractures at the ends of the plates or persistent infections were reported to have occurred in 18% of the patients. This technique can be useful if the bone defect is not substantial and there are no preexisting soft-tissue coverage issues.

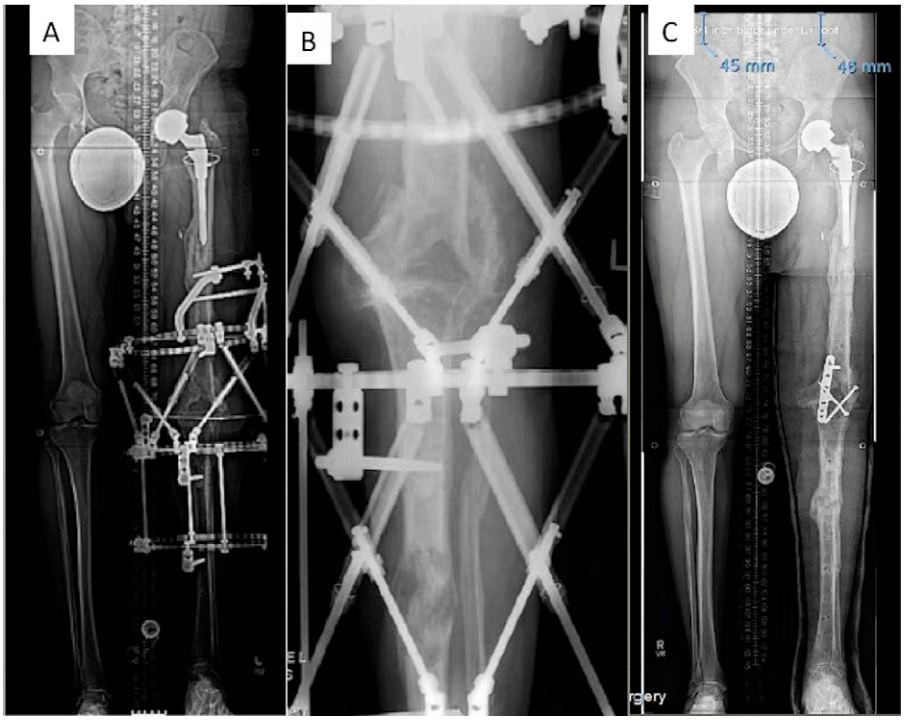

Fig. 5

Figs. 5-A, 5-B, and 5-C The use of a circular frame and its removal after treatment of an infected TKA that failed in a patient with a total hip replacement on the ipsilateral side. **Fig. 5-A** After failure of the infected TKA, arthrodesis of the left knee was performed using a circular fixator to achieve union and perform simultaneous tibial lengthening in the presence of the left total hip replacement. **Fig. 5-B** Anteroposterior radiograph of the knee demonstrates poor bone stock at the knee arthrodesis docking site. **Fig. 5-C** Anteroposterior radiograph made 2 weeks postoperatively demonstrates a secondary stabilization procedure with plates and screws to overcome the anterior cortical deficiency and protect the knee fusion site from fracture after frame removal.

Combined Surgical Options

Using a circular external fixation device to gradually shorten the bone defect at the fusion site and then removing the fixator and replacing it with an IMN is an example of combined surgical techniques. The advantage of this technique is minimizing the time required for the frame to be in place until achieving a full consolidation at the fusion site and/or lengthening site[31]. The IMN can also protect the fusion site against fracture. The use of an antibiotic cement-coated interlocking IMN can also provide temporary local antibiotics that may protect against further infection. Another indication for the use of a combined surgical technique is to provide stabilization of the fusion site, either with an IMN or plate and screws, after frame removal in patients with poor bone stock at the fusion site.

Salvage Options for Massive Bone Defects

Massive bone loss (generally >6 cm) after failed TKA is not uncommon when patients undergo multiple revisions[18,57,58]. In this population, isolated shortening of the bone defect at the fusion site would result in a substantial LLD. Additionally, many of these patients are not candidates for bone-lengthening procedures because of advanced age or substantial medical comorbidities. The management goal in these patients is to preserve the leg length as well as minimize the number of surgical procedures. Several techniques can be utilized, including a modified fusion technique as described by Voss[59]. In the treatment of an 82-year-old man who had 4 prior failed revisions because of infected TKAs, he used a long IMN with a cement spacer to fill the bone defect after explantation. The patient maintained his walking ability 4 years postoperatively. Since then, similar techniques have been developed using a short, press-fit, modular IMN and antibiotic-impregnated cement spacer without bone-on-bone fusion. Iacono et al., in a report on the results of this technique in 22 patients, showed substantial improvement in functional outcome at a mean follow-up of 34 months compared with the preoperative status[60]. The average LLD in their study was 1 cm. Hawi et al. echoed these results in a report on 27 patients who had been managed with this technique in a single-stage intervention[61]. Another technique is the use of vascularized fibular bone graft (VFBG) to bridge the bone defect. Rasmussen et al. reported successful outcomes with the use of VFBG to achieve knee fusion in 13 patients[58]. Four of those patients underwent knee arthrodesis because of failure of an infected TKA. The disadvantages of this strategy are that it is technically demanding, provides little intrinsic stability, and involves a longer operative time than more traditional methods. Another drawback is that single-stage intervention is not possible with this technique in actively infected TKAs. Lastly, Trabecular Metal (Zimmer Biomet)

TABLE II Grade of Recommendations

Recommendation	Grade*
The use of an IMN for knee arthrodesis results in higher fusion rates than the use of external fixation devices.	B
Knee arthrodesis after failure of an infected TKA may provide superior functional outcome and ambulatory status than above-the-knee amputation.	C
Knee arthrodesis may be considered after 1 attempt at 2-stage revision TKA to increase the success rates of fusion.	C
Massive bone defects after failure of an infected TKA can be managed with artificial fusion techniques with acceptable short-term outcomes.	C
The use of the antibiotic cement-coated interlocking IMN may expand the indications for achieving knee fusion in a single stage intervention.	I

*According to Wright[63], grade A indicates good evidence (Level-I studies with consistent findings) for or against recommending intervention; grade B, fair evidence (Level-II or III studies with consistent findings) for or against recommending intervention; grade C, poor-quality evidence (Level-IV or V studies with consistent findings) for or against recommending intervention; and grade I, insufficient or conflicting evidence not allowing a recommendation for or against intervention.

cones with a long IMN can be used to bridge large bone defects. Peterson et al. reported the results of a novel technique used for knee arthrodesis in 6 patients who had failure of infected TKAs[57]. Those authors used Trabecular Metal cones along with an IMN and autograft to bridge a massive bone defect and perform the knee arthrodesis. Five patients had a solid fusion during the follow-up period. However, 1 patient had a septic nonunion and underwent transfemoral amputation.

In this population of patients with massive bone loss, the salvage surgical option should be selected on the basis of the surgeon's training and experience, with the goal of minimizing the number of surgical procedures while preserving leg length and function.

Our Preferred Treatment Strategy and Technique

We tailor the surgical options on the basis of the clinical circumstances and indications. Our goals are to (1) achieve solid fusion, (2) preserve length, and (3) control and/or prevent recurrent infection in 1 surgical intervention when possible. Figure 3 summarizes our preferred treatment strategies.

When using an antibiotic cement-coated IMN, our preference is to lock the nail proximally into the femoral neck, through a designated hole in the nail, to prophylactically protect the femoral neck from a potential fragility fracture in the future. We typically mix 2 g of vancomycin and 3.4 g of tobramycin (unless other antibiotics are indicated on the basis of a prior culture sensitivity) with each 40 g of Simplex bone cement (Stryker Orthopaedics). In fungal infections, voriconazole (300 mg/40 g cement) is added to this mixture. We prefer to use a silicone tube (Tygon Tubing; Saint-Gobain) to fabricate the IMN (Fig. 4). Unlike a plastic chest tube, the silicone tube does not melt or stick to the cement. If a chest tube is chosen, then coating the inside portion of the tube with mineral oil is necessary before cement insertion[62]. The inner diameter of the chosen silicone tube is generally 1.5 to 2.5 mm larger than the selected nail diameter. Therefore, the nail diameter that is chosen preoperatively is typically 1.5 to 2.5 mm smaller than the medullary canal fit in both the femur and the tibia to account for the outer diameter of cement coating. We routinely utilize an antibiotic cement-coated IMN in knee arthrodeses for patients with a history of infection or in patients with active infection with a known nonvirulent organism after failed TKA.

In our practice, we only use locking plates for the prevention of fracture after circular frame removal in the patients with poor bone stock (Fig. 5).

In patients with massive bone loss and those who are not candidates for lengthening, we utilize a long IMN and a cannulated, antibiotic-impregnated, cylindrical cement spacer to bridge the bone defect and to function as an artificial fusion (Fig. 1). This provides the option for removal of the IMN and the spacer as needed. Although this strategy is promising as a salvage option, the long-term results remain to be determined.

Overview

Solid knee fusion after failure of an infected TKA can provide a stable extremity that allows weight-bearing. Knee arthrodesis may be considered after 1 attempt at 2-stage revision to minimize bone loss and optimize bone quality at the fusion site. Various surgical techniques are available, and surgeons should utilize these on the basis of the clinical indications and evidence-based recommendations (Table II). ■

Asim M. Makhdom, MD, MSc, FRCSC[1]
Austin Fragomen, MD[1]
S. Robert Rozbruch, MD[1]

[1]Hospital for Special Surgery, Weill Cornell Medicine, Cornell University, New York, NY

E-mail address for S.R. Rozbruch: RozbruchSR@HSS.EDU

ORCID iD for A.M. Makhdom: 0000-0002-5338-703X
ORCID iD for A. Fragomen: 0000-0002-9031-9079
ORCID iD for S.R. Rozbruch: 0000-0003-1632-4600

References

1. Kurtz S, Ong K, Lau E, Mowat F, Halpern M. Projections of primary and revision hip and knee arthroplasty in the United States from 2005 to 2030. J Bone Joint Surg Am. 2007 Apr;89(4):780-5.

2. Tanzer M, Makhdom AM. Preoperative planning in primary total knee arthroplasty. J Am Acad Orthop Surg. 2016 Apr;24(4):220-30.

3. Wang CJ, Huang TW, Wang JW, Chen HS. The often poor clinical outcome of infected total knee arthroplasty. J Arthroplasty. 2002 Aug;17(5):608-14.

4. Blom AW, Brown J, Taylor AH, Pattison G, Whitehouse S, Bannister GC. Infection after total knee arthroplasty. J Bone Joint Surg Br. 2004 Jul;86(5):688-91.

5. Gottfriedsen TB, Schrøder HM, Odgaard A. Knee arthrodesis after failure of knee arthroplasty: a nationwide register-based study. J Bone Joint Surg Am. 2016 Aug 17;98(16):1370-7.

6. Rodriguez-Merchan EC. Knee fusion or above-the-knee amputation after failed two-stage reimplantation total knee arthroplasty. Arch Bone Jt Surg. 2015 Oct;3(4):241-3.

7. Chen AF, Kinback NC, Heyl AE, McClain EJ, Klatt BA. Better function for fusions versus above-the-knee amputations for recurrent periprosthetic knee infection. Clin Orthop Relat Res. 2012 Oct;470(10):2737-45.

8. Son MS, Lau E, Parvizi J, Mont MA, Bozic KJ, Kurtz S. What are the frequency, associated factors, and mortality of amputation and arthrodesis after a failed infected TKA? Clin Orthop Relat Res. 2017 Dec;475(12):2905-13.

9. Fedorka CJ, Chen AF, McGarry WM, Parvizi J, Klatt BA. Functional ability after above-the-knee amputation for infected total knee arthroplasty. Clin Orthop Relat Res. 2011 Apr;469(4):1024-32.

10. Prendki V, Ferry T, Sergent P, Oziol E, Forestier E, Fraisse T, Tounes S, Ansart S, Gaillat J, Bayle S, Ruyer O, Borlot F, Le Falher G, Simorre B, Dauchy FA, Greffe S, Bauer T, Bell EN, Martha B, Martinot M, Froidure M, Buisson M, Waldner A, Lemaire X, Bosseray A, Maillet M, Charvet V, Barrelet A, Wyplosz B, Noaillon M, Denes E, Beretti E, Berlioz-Thibal M, Meyssonnier V, Fourniols E, Tliba L, Eden A, Jean M, Arvieux C, Guignery-Kadri K, Ronde-Oustau C, Hansmann Y, Belkacem A, Bouchand F, Gavazzi G, Herrmann F, Stirnemann J, Dinh A. Prolonged suppressive antibiotic therapy for prosthetic joint infection in the elderly: a national multicentre cohort study. Eur J Clin Microbiol Infect Dis. 2017 Sep;36(9):1577-85. Epub 2017 Apr 4.

11. Falahee MH, Matthews LS, Kaufer H. Resection arthroplasty as a salvage procedure for a knee with infection after a total arthroplasty. J Bone Joint Surg Am. 1987 Sep;69(7):1013-21.

12. Scott SJ, Hennessey MS, Parkinson RW, Molloy AP. Long-term outcome of the 'Beefburger' procedure in patients unsuitable for two-stage revision following infected total knee replacement. Knee. 2001 Dec;8(4):281-6.

13. MacDonald JH, Agarwal S, Lorei MP, Johanson NA, Freiberg AA. Knee arthrodesis. J Am Acad Orthop Surg. 2006 Mar;14(3):154-63.

14. Wiedel JD. Salvage of infected total knee fusion: the last option. Clin Orthop Relat Res. 2002 Nov;404:139-42.

15. Capozzi JD, Rhodes R, Chen D. Discussing treatment options. J Bone Joint Surg Am. 2009 Mar 1;91(3):740-2.

16. Wilde AH, Stearns KL. Intramedullary fixation for arthrodesis of the knee after infected total knee arthroplasty. Clin Orthop Relat Res. 1989 Nov;248:87-92.

17. Behr JT, Chmell SJ, Schwartz CM. Knee arthrodesis for failed total knee arthroplasty. Arch Surg. 1985 Mar;120(3):350-4.

18. Hak DJ, Lieberman JR, Finerman GA. Single plane and biplane external fixators for knee arthrodesis. Clin Orthop Relat Res. 1995 Jul;316:134-44.

19. Brodersen MP, Fitzgerald RH Jr, Peterson LF, Coventry MB, Bryan RS. Arthrodesis of the knee following failed total knee arthroplasty. J Bone Joint Surg Am. 1979 Mar;61(2):181-5.

20. Barton TM, White SP, Mintowt-Czyz W, Porteous AJ, Newman JH. A comparison of patient based outcome following knee arthrodesis for failed total knee arthroplasty and revision knee arthroplasty. Knee. 2008 Mar;15(2):98-100. Epub 2008 Feb 21.

21. Gomez MM, Tan TL, Manrique J, Deirmengian GK, Parvizi J. The fate of spacers in the treatment of periprosthetic joint infection. J Bone Joint Surg Am. 2015 Sep 16;97(18):1495-502.

22. Cancienne JM, Granadillo VA, Patel KJ, Werner BC, Browne JA. Risk factors for repeat debridement, spacer retention, amputation, arthrodesis, and mortality after removal of an infected total knee arthroplasty with spacer placement. J Arthroplasty. 2018 Feb;33(2):515-20. Epub 2017 Sep 5.

23. Kahlenberg CA, Hernandez-Soria A, Cross MB. Poor prognosis of patients treated for periprosthetic joint infection. HSS J. 2017 Feb;13(1):96-9. Epub 2016 Jun 1.

24. Blumenfeld TJ. Rethinking the definition of success in the management of a periprosthetic joint infection: Commentary on an article by Miguel M. Gomez, MD, et al.: "The fate of spacers in the treatment of periprosthetic joint infection". J Bone Joint Surg Am. 2015 Sep 16;97(18):e64.

25. Kheir MM, Tan TL, Gomez MM, Chen AF, Parvizi J. Patients with failed prior two-stage exchange have poor outcomes after further surgical intervention. J Arthroplasty. 2017 Apr;32(4):1262-5. Epub 2016 Oct 20.

26. Wu CH, Gray CF, Lee GC. Arthrodesis should be strongly considered after failed two-stage reimplantation TKA. Clin Orthop Relat Res. 2014 Nov;472(11):3295-304.

27. Damron TA, McBeath AA. Arthrodesis following failed total knee arthroplasty: comprehensive review and meta-analysis of recent literature. Orthopedics. 1995 Apr;18(4):361-8.

28. Siller TN, Hadjipavlou A. Knee arthrodesis: long-term results. Can J Surg. 1976 May;19(3):217-9.

29. Conway JD, Mont MA, Bezwada HP. Arthrodesis of the knee. J Bone Joint Surg Am. 2004 Apr;86(4):835-48.

30. Rozbruch SR, Ilizarov S, Blyakher A. Knee arthrodesis with simultaneous lengthening using the Ilizarov method. J Orthop Trauma. 2005 Mar;19(3):171-9.

31. Kuchinad R, Fourman MS, Fragomen AT, Rozbruch SR. Knee arthrodesis as limb salvage for complex failures of total knee arthroplasty. J Arthroplasty. 2014 Nov;29(11):2150-5. Epub 2014 Jul 4.

32. Puranen J, Kortelainen P, Jalovaara P. Arthrodesis of the knee with intramedullary nail fixation. J Bone Joint Surg Am. 1990 Mar;72(3):433-42.

33. Mabry TM, Jacofsky DJ, Haidukewych GJ, Hanssen AD. Comparison of intramedullary nailing and external fixation knee arthrodesis for the infected knee replacement. Clin Orthop Relat Res. 2007 Nov;464:11-5.

34. Bargiotas K, Wohlrab D, Sewecke JJ, Lavinge G, DeMeo PJ, Sotereanos NG. Arthrodesis of the knee with a long intramedullary nail following the failure of a total knee arthroplasty as the result of infection. Surgical technique. J Bone Joint Surg Am. 2007 Mar;89(Suppl 2 Pt.1):103-10.

35. Friedrich MJ, Schmolders J, Wimmer MD, Strauss AC, Ploeger MM, Wirtz DC, Gravius S, Randau TM. Two-stage knee arthrodesis with a modular intramedullary nail due to septic failure of revision total knee arthroplasty with extensor mechanism deficiency. Knee. 2017 Oct;24(5):1240-6. Epub 2017 Jun 13.

36. Gallusser N, Goetti P, Luyet A, Borens O. Knee arthrodesis with modular nail after failed TKA due to infection. Eur J Orthop Surg Traumatol. 2015 Dec;25(8):1307-12. Epub 2015 Oct 1.

37. Cierny G 3rd, Mader JT, Penninck JJ. A clinical staging system for adult osteomyelitis. Clin Orthop Relat Res. 2003 Sep;414:7-24.

38. Barger J, Fragomen AT, Rozbruch SR. Antibiotic-coated interlocking intramedullary nail for the treatment of long-bone osteomyelitis. JBJS Rev. 2017 Jul;5(7):e5.

39. Metsemakers WJ, Reul M, Nijs S. The use of gentamicin-coated nails in complex open tibia fracture and revision cases: a retrospective analysis of a single centre case series and review of the literature. Injury. 2015 Dec;46(12):2433-7. Epub 2015 Oct 8.

40. Pawar A, Dikmen G, Fragomen A, Rozbruch SR. Antibiotic-coated nail for fusion of infected Charcot ankles. Foot Ankle Int. 2013 Jan;34(1):80-4.

41. De Vil J, Almqvist KF, Vanheeren P, Boone B, Verdonk R. Knee arthrodesis with an intramedullary nail: a retrospective study. Knee Surg Sports Traumatol Arthrosc. 2008 Jul;16(7):645-50. Epub 2008 Mar 29.

42. Lee S, Jang J, Seong SC, Lee MC. Distraction arthrodesis with intramedullary nail and mixed bone grafting after failed infected total knee arthroplasty. Knee Surg Sports Traumatol Arthrosc. 2012 Feb;20(2):346-55. Epub 2011 Nov 1.

43. Leroux B, Aparicio G, Fontanin N, Ohl X, Madi K, Dehoux E, Diallo S. Arthrodesis in septic knees using a long intramedullary nail: 17 consecutive cases. Orthop Traumatol Surg Res. 2013 Jun;99(4):399-404. Epub 2013 Apr 23.

44. Garcia-Lopez I, Aguayo MA, Cuevas A, Navarro P, Prieto C, Carpintero P. Knee arthrodesis with the Vari-Wall nail for treatment of infected total knee arthroplasty. Acta Orthop Belg. 2008 Dec;74(6):809-15.

45. Razii N, Abbas AM, Kakar R, Agarwal S, Morgan-Jones R. Knee arthrodesis with a long intramedullary nail as limb salvage for complex periprosthetic infections. Eur J Orthop Surg Traumatol. 2016 Dec;26(8):907-14. Epub 2016 Jul 29.

46. Talmo CT, Bono JV, Figgie MP, Sculco TP, Laskin RS, Windsor RE. Intramedullary arthrodesis of the knee in the treatment of sepsis after TKR. HSS J. 2007 Feb;3(1):83-8.

47. Bruno AA, Kirienko A, Peccati A, Dupplicato P, De Donato M, Arnaldi E, Portinaro N. Knee arthrodesis by the Ilizarov method in the treatment of total knee arthroplasty failure. Knee. 2017 Jan;24(1):91-9. Epub 2016 Nov 18.

48. Klinger HM, Spahn G, Schultz W, Baums MH. Arthrodesis of the knee after failed infected total knee arthroplasty. Knee Surg Sports Traumatol Arthrosc. 2006 May;14(5):447-53. Epub 2005 Aug 30.

49. Van Rensch PJ, Van de Pol GJ, Goosen JH, Wymenga AB, De Man FH. Arthrodesis of the knee following failed arthroplasty. Knee Surg Sports Traumatol Arthrosc. 2014 Aug;22(8):1940-8. Epub 2013 May 26.

50. Yeoh D, Goddard R, Macnamara P, Bowman N, Miles K, East D, Butler-Manuel A. A comparison of two techniques for knee arthrodesis: the custom made intramedullary Mayday nail versus a monoaxial external fixator. Knee. 2008 Aug;15(4):263-7. Epub 2008 Apr 23.

51. Domingo LJ, Caballero MJ, Cuenca J, Herrera A, Sola A, Herrero L. Knee arthrodesis with the Wichita fusion nail. Int Orthop. 2004 Feb;28(1):25-7. Epub 2003 Oct 10.

52. Incavo SJ, Lilly JW, Bartlett CS, Churchill DL. Arthrodesis of the knee: experience with intramedullary nailing. J Arthroplasty. 2000 Oct;15(7):871-6.

53. Wood JH, Conway JD. Advanced concepts in knee arthrodesis. World J Orthop. 2015 Mar 18;6(2):202-10.

54. Lai KA, Shen WJ, Yang CY. Arthrodesis with a short Huckstep nail as a salvage procedure for failed total knee arthroplasty. J Bone Joint Surg Am. 1998 Mar;80(3):380-8.

55. Birch JG, Samchukov ML. Use of the Ilizarov method to correct lower limb deformities in children and adolescents. J Am Acad Orthop Surg. 2004 May-Jun;12(3):144-54.

56. Nichols SJ, Landon GC, Tullos HS. Arthrodesis with dual plates after failed total knee arthroplasty. J Bone Joint Surg Am. 1991 Aug;73(7):1020-4.

57. Peterson BE, Bal S, Aggarwal A, Crist BD. Novel technique: knee arthrodesis using trabecular metal cones with intramedullary nailing and intramedullary autograft. J Knee Surg. 2016 Aug;29(6):510-5. Epub 2015 Nov 9.

58. Rasmussen MR, Bishop AT, Wood MB. Arthrodesis of the knee with a vascularized fibular rotatory graft. J Bone Joint Surg Am. 1995 May;77(5):751-9.

59. Voss FR. A new technique of limb salvage after infected revision total knee arthroplasty: artificial fusion. J Arthroplasty. 2001 Jun;16(4):524-8.

60. Iacono F, Bruni D, Lo Presti M, Raspugli G, Bondi A, Sharma B, Marcacci M. Knee arthrodesis with a press-fit modular intramedullary nail without bone-on-bone fusion after an infected revision TKA. Knee. 2012 Oct;19(5):555-9. Epub 2012 Feb 15.

61. Hawi N, Kendoff D, Citak M, Gehrke T, Haasper C. Septic single-stage knee arthrodesis after failed total knee arthroplasty using a cemented coupled nail. Bone Joint J. 2015 May;97-B(5):649-53.

62. Kim JW, Cuellar DO, Hao J, Seligson D, Mauffrey C. Custom-made antibiotic cement nails: a comparative study of different fabrication techniques. Injury. 2014 Aug;45(8):1179-84. Epub 2014 Mar 21.

63. Wright JG. Revised grades of recommendation for summaries or reviews of orthopaedic surgical studies. J Bone Joint Surg Am. 2006 May;88(5):1161-2.